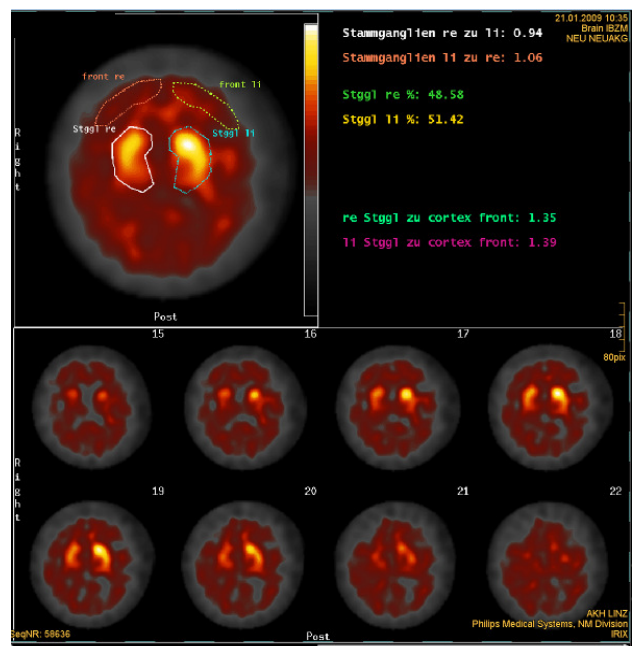
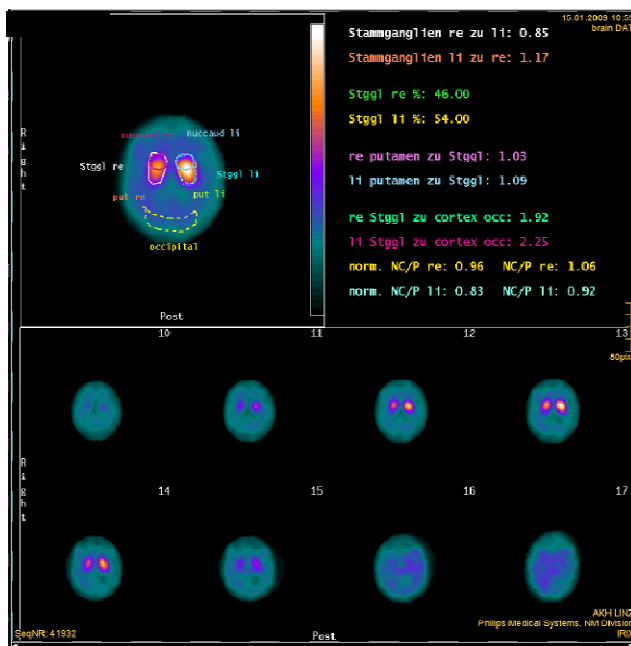
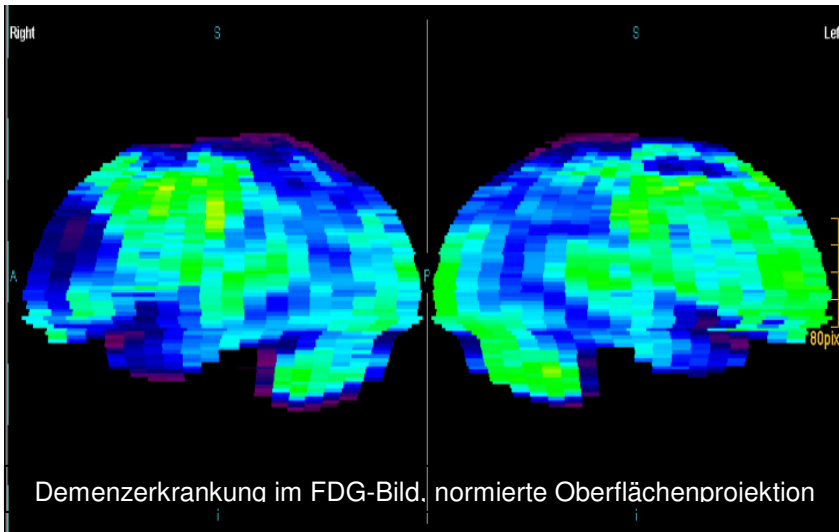
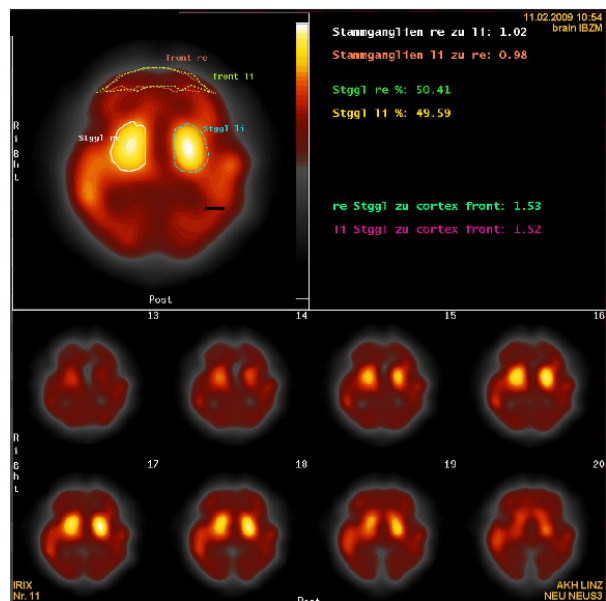
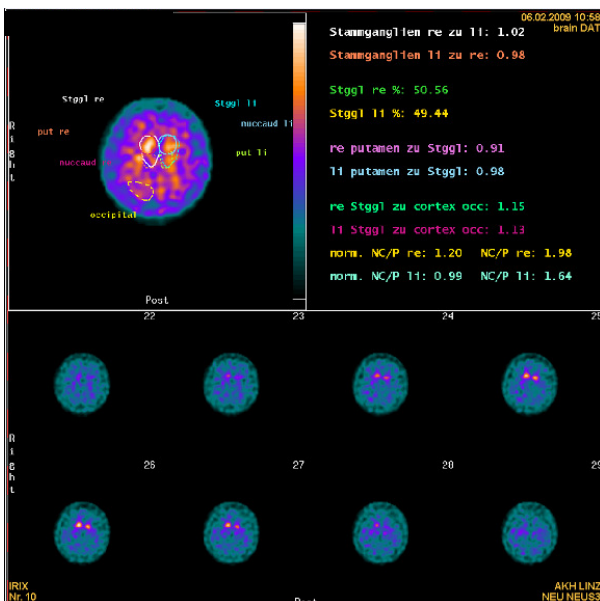


Befundbeispiele für Neurologische Untersuchungen



DAT- und IBZM-scan bei atypischem Parkinsonsyndrom, rechts > linksseitig ausgeprägt



DAT- und IBZM-scan bei klassischer Parkinsonerkrankung